

See discussions, stats, and author profiles for this publication at: <https://www.researchgate.net/publication/322206971>

Application of Ozone Nanobubble Water (ONBW) to Peri-Implantitis Treatment

Article · January 2017

DOI: 10.4172/2161-1122.1000466

CITATIONS

2

READS

637

3 authors, including:



Shinichi Arakawa

Tokyo Medical and Dental University

39 PUBLICATIONS 787 CITATIONS

[SEE PROFILE](#)



Anongwee Leewananthawet

Chiang Mai University

2 PUBLICATIONS 9 CITATIONS

[SEE PROFILE](#)

Some of the authors of this publication are also working on these related projects:



Isolation and identification of a cytopathic activity in *Tannerella forsythia* [View project](#)

Application of Ozone Nanobubble Water (ONBW) to Peri-Implantitis Treatment

Shinichi Arakawa^{1*}, Mitsuru Sugisawa² and Anongwee Leewananthawet^{1,3}

¹Graduate School, Department of Lifetime Oral Health Care Science, Tokyo Medical and Dental University, Japan

²Sugisawa Dental Clinic, Japan

³Graduate School, Department of Periodontology, Tokyo Medical and Dental University, Japan

*Corresponding author: Shinichi Arakawa, Professor, Graduate School, Department of Lifetime Oral Health Care Science, Tokyo Medical and Dental University, 1-5-45, Yushima, Bunkyo-Ku, Tokyo, Japan, 113-8510, Tel: +81-3-5803-4968; Fax: +81-3-5803-0239; E-mail: shinperi@tmd.ac.jp

Received date: October 24, 2017; Accepted date: November 27, 2017; Published date: December 04, 2017

Copyright: © 2017 Arakawa S, et al. This is an open-access article distributed under the terms of the Creative Commons Attribution License, which permits unrestricted use, distribution, and reproduction in any medium, provided the original author and source are credited.

Abstract

In this case report, we investigated the effects of Ozone nanobubble water (ONBW) on peri-implantitis lesions with non-surgical treatment. ONBW preserves the ozone gas nucleus for more than 6 months although half life time of ozone water was almost 30 minutes. ONBW exerts anti-microbial activity towards several kinds of bacteria including periodontopathic bacteria and cariogenic bacteria. There was no cytotoxicity against oral epithelial and mucosa cells. The Advanced quick bonding (AQB) implants on 19 and 20 were placed on a patient 43 years old female four years ago. The chief complaint of her was swelling at the site of 20. The patient presented swollen at peri-implant area, Bleeding of probing (BOP), and probing depth (PD)=6 mm at buccal site of an implant of 20. There was no findings of mobility at concerned implant. The bone resorption and a radiolucent part around the implant was confirmed with periapical radiograph. The amount of bone loss was 5.0 and 6.5mm at mesial and distal site of 20, respectively. This peri-implantitis was evaluated the case required surgical therapy. In addition to mechanical plaque control, the patient received regular professional oral hygiene treatment and irrigation with ONBW every week at 100mL each. And also, regarding chemical plaque control, the irrigation for pockets was also performed at home by the patient at a frequency of three times a day every day. After 12 weeks, soft tissues of the peri-implant presented no clinical signs of inflammation and BOP, and PD was 3 mm. The bone levels did not change significantly as demonstrated by the follow-up roentgenography taken after 3 years. Microbiologically, the number of red-complex of periodontopathic bacteria have been decreased substantially. This case report supports that ONBW might be effective and predictable as an adjunctive therapy for peri-implantitis. To the best our knowledge, this is the first report on describing the peri-implantitis treatment with ONBW.

Keywords: Ozone nanobubble water (ONBW); Peri-implantitis; Bactericidal activity

Abbreviations ONBW: Ozone nanobubble water

Introduction

Peri-implant diseases were classified in two types such as peri-implant mucositis and peri-implantitis. The peri-implant mucositis is a reversible inflammatory disease localized at the mucosa. On the other hand, peri-implantitis is characterized by an inflammatory status around an implant, which included both inflammation at soft tissue and progressive bone resorption circumferentially around an osseointegrated dental implant [1]. There are some studies describing the prevalence of peri-implantitis. In a review, the prevalence of peri-implantitis varied from 15% to 56% at the patient level [2]. In another study with samples of 245 patients from a private practice, the prevalence of peri-implantitis varied from 12% to 22% [3].

These inflammation and infection at peri-implant supportive tissues were associated with biofilm composed with pathogenic microorganisms [4] which mediated inflammatory soft tissue response at soft tissue and bone at peri-implant area [2]. Rosenberg et al. reported that peri-implantitis lesions have similar microbiota to those of chronic periodontitis [5]. Gloria IL, et al. reported in their systemic

review that healthy implants and peri-implantitis are colonized by periodontopathic microorganisms. *Porphyromonas gingivalis* and especially *Prevotella intermedia/nigrescens* may be more frequent in diseased implants. Moreover, peri-implantitis is characterized by the colonization of non-cultivable asaccharolytic anaerobic gram-positive and gram-negative rods [6].

For treatment of peri-implantitis, several therapies have been reported [7-9]. Non-surgical treatments usually include debridement with curretts or air abrasion, and these can be with antibiotic therapy [10,11]. For the latter, chlorhexidine rinses or deposits or erbium:yttrium-aluminum-garnet (Er: YAG) laser application has been used. Surgical treatments involve access to lesion followed by debridement, in some cases, regenerative therapy such as bone grafts or barrier membranes [12]. Since there were few long-term prospective randomized studies, ideal peri-implantitis therapies have not been elucidated. However, the cumulative interceptive supportive therapy (CIST) protocol serves as the guideline for the treatment of the peri-implantitis [4,13].

Ozone has been accepted as a treatment modality in many countries as ozone therapy. Ozone is composed of a three-atom molecule consisting of three oxygen atoms. Ozone has been utilized in both an aqueous and gaseous form in medicine and dentistry [14]. Ozone therapy provides antimicrobial, anti-inflammatory, and wound healing effects [15-17]. Additionally, it has been reported that ozone therapy

also has several kinds of desired effects, such as immune-stimulating, anti-hypoxic, analgesic, detoxicating and biosynthetic ones [18]. It was used in several empirical studies as a therapeutic agent for chronic wounds (like trophic and ischemic ulcers and diabetic wounds, etc.) [19]. The use of ozone was also examined in viral-fungal and bacterial infections, ocular, ischemic, orthopedic, hematological, neurodegenerative, pulmonary, renal and dermatological diseases; and in age-dependent macular degeneration [20]. In dentistry, it has also been used in the gaseous or aqueous form to inhibit bacterial proliferation, obtain epithelial wound-healing, enhance local oxygen supply, eliminate cariogenic bacteria, disinfect the root canals, and promote hemostasis [21-23]. Regarding the cytotoxicity of ozone, there were some reports described that aqueous ozone is highly biocompatible with fibroblasts, cementoblasts, and epithelial cells [24-26], suggesting that aqueous ozone would be suitable for treating oral infectious diseases such as periodontal diseases. Although a half-life of ozonated water is about only 30 min, CHIBA and TAKAHASHI [27] developed a patented procedure to produce ozone nano-bubble water (ONBW) which name has recently been changed to Ozone Ultrafine Bubble Water approved by International Organization for Standardization (ISO). The diameter of a nano-bubble is less than 100 nm, and is produced by the collapse of a micro-bubble ($\leq 50 \mu\text{m}$ in diameter) in an electrolyte solution by means of a physical stimulus. ONBW keeps the oxidation ability as aqueous ozone for more than 6 months when protected from the exposure to ultraviolet rays [28]. Since ONBW is highly stabilized, it is easy and convenient to use as a disinfectant solution at both home and clinical room. Hayakumo S, et al. reported that ONBW possesses the potent bactericidal activity against periodontopathic bacteria without exhibiting toxicity to human oral tissues [29] and that irrigation with ONBW at subgingival area may be an effective antimicrobial adjunct to mechanical instrumentation in the management of periodontal infections [30]. This study reports the effect of ONBW on treating peri-implantitis.

Case Report

A 43-year old female patient with no local and systemic contraindications to oral surgery came to the dental clinic of Sugisawa Dental Clinic in 2015. This patient received implant treatment at 20 and 19 in 2011. The implants embedded were AQB implant (Advance Co., Tokyo, Japan) (4MS: 4.00 mm in diameter and 10.00mm in length at 20 and 3MS: 3.00 mm in diameter and 10.00 mm in length at 19). The patient showed sign of swelling at peri-implant soft tissues, associated with Bleeding of probing (BOP), probing depth (PD)=6 mm at buccal site of an implant of 20 (Figures 1 and 2).

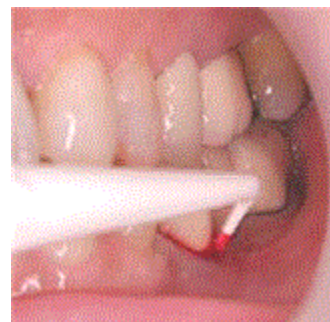

Figure 1: Oral photograph in 2015. The patient showed sign of swelling of peri-implant soft tissues, associated with Bleeding of probing (BOP), probing depth (PD)=6mm at buccal site of an implant of 20.

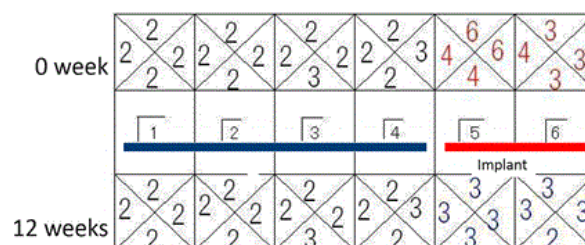

Figure 2: The patient showed swelling of peri-implant soft tissues, associated with Bleeding of probing (BOP), probing depth (PD)=6 mm at buccal site of an implant of 20.

No clinical signs of mobility were recorded. However, the defect consisted of a circumferential bone resorption and a radiolucent area delimitating the implant were confirmed by periapical radiograph. The amount of bone loss was 5.0 and 6.5 mm at mesial and distal site of 20, respectively (Figure 3). According to CIST, surgical therapy was necessary in this case [4].

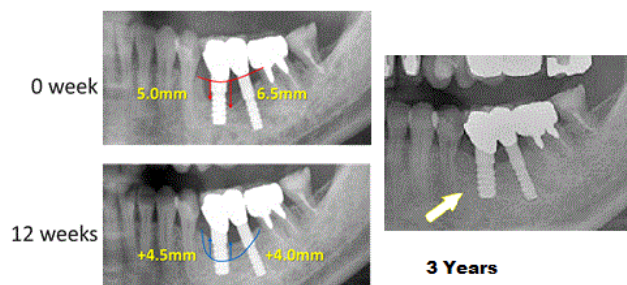


Figure 3: The amount of bone loss was 5.0 and 6.5mm at mesial and distal site of 20, respectively at 0 week. The mesial and distal levels of the peri-implant marginal bone were recovered radiographically at 12 weeks and this condition was stable following 3years.

However, in this case, we selected the mechanical plaque control using sonic a toothbrush and an interdental brush, and chemical

plaque control using ONBW (KYOCERA Corporation, Kyoto, Japan) which contains about 1.5 ppm of ozone as gas nucleus (Figure 4). The patient received regular professional oral hygiene procedures and irrigation with ONBW every week at 100 mL each by the dentist. Moreover, the irrigation for pockets was performed at home by herself at a frequency of three times a day every day.

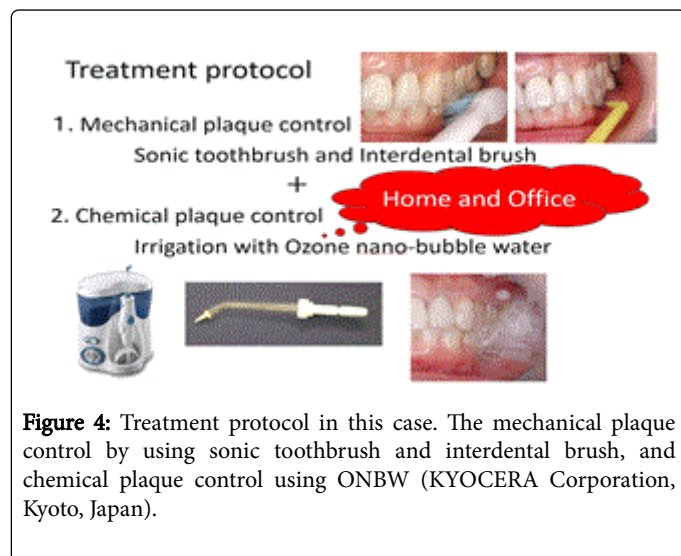


Figure 4: Treatment protocol in this case. The mechanical plaque control by using sonic toothbrush and interdental brush, and chemical plaque control using ONBW (KYOCERA Corporation, Kyoto, Japan).

After 12 weeks, soft tissues of the peri-implant presented no clinical signs of inflammation and BOP, and PD was 3 mm (Figures 2 and 5).

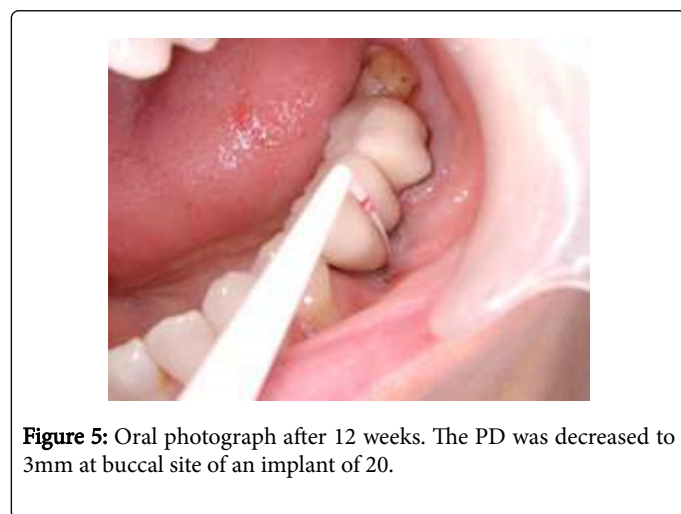


Figure 5: Oral photograph after 12 weeks. The PD was decreased to 3mm at buccal site of an implant of 20.

Species	0W	12W
<i>A. actinomycetemcomitans</i>	<10	<10
<i>P. intermedia</i>	<10	<10
<i>P. gingivalis</i>	7,800 (5.57%)	<10
<i>T. forsythia</i>	5,300 (3.79%)	58 (1.31%)
<i>T. denticola</i>	1,000 (0.71%)	<10
Total	1,40,000	4,400

Table 1: The number of red-complex of periodontopathic bacteria have been decreased substantially, *Porphyromonas gingivalis*, *Tannerella*

for sythia, and *Treponema denticola*: 7800 to <10, 5300 to 58, and 1000 to <10, respectively.

Recovery of the mesial and distal levels of the peri-implant marginal bone were confirmed radiographically (Figure 3). The bone levels were stable which demonstrated by the follow-up roentgenography taken after 3 years (Figure 2). Microbiologically, the number of bacteria at the buccal site of 20 was evaluated by using real-time PCR (polymerase chain reaction). The number of red-complex of periodontopathic bacteria have been decreased substantially, *Porphyromonas gingivalis*, *Tannerella forsythia*, and *Treponema denticola*: 7800 to <10, 5300 to 58, and 1000 to <10, respectively (Table 1). Furthermore, we have other cases in which good healing were obtained equally by treating with ONBW (date not shown).

Discussion

The present case report described the clinical outcome obtained following a non-surgical treatment of peri-implantitis by using ONBW. We have already carried out clinical and microbiological examination in order to evaluate the effects of ONBW irrigation in addition to mechanical debridement for periodontal treatment. It was revealed that all clinical parameters were improved and the mean total numbers of bacteria in subgingival plaque were reduced. We concluded that these results suggested that subgingival irrigation with ONBW may be effective in treating peri-implantitis. As far as we know, this is the first report to describe the peri-implantitis treatment with ONBW.

In this report, irrigation with ONBW has been proven to be an effective additional treatment with mechanical plaque control. In 2004, Lang et al. presented valuable guidelines based on a diagnostic therapeutic algorithm [13]. A surgical approach in addition to the implant surface decontamination and antibiotic therapy should be performed for peri-implantitis treatment. However, in this case bone regeneration around the implant was obtained by using ONBW. Gloria I L, et al. reported that heterogeneous bacteria including periodontopathic bacteria, uncultivable asaccharolytic anaerobic gram-positive rods and other uncultivable gram-negative rods and opportunistic microorganisms were infected in peri-implantitis lesions [6].

As we have reported, ONBW possesses microbicidal activity against a variety of periodontopathic bacteria [30]. By irrigation with ONBW, the number of bacteria caused peri-implantitis might be decreased and the ability of HA to provide osseous conduction capacity might be induced. Furthermore, the basic mechanisms of action of ozone in medicine have been clarified for many years [31]. The possible profits of ozone in medicine are generally assigned to its antimicrobial, disinfectant, and healing effects. In addition, Bocci et al. have described that a small dose of ozone can stimulate several useful biochemical reactions and activate the signal transduction for antioxidant system [32, 33]. The microbicidal properties of ozone have made the utilization of ozone in dentistry [34]. Ozone has also been used for the treatment for early carious lesions, ulcerations, and herpetic lesions of the oral mucosa, the sterilization of cavities and root canals, and periodontal pockets, and the cleaning of dentures [35-37]. Erdemci F, et al. reported on the investigation of the effects of systemic and topical ozone utilization in alveolar bone regeneration after tooth extraction. They concluded that postoperative long-term systemic ozone application can accelerate alveolar bone healing following extraction [38]. Ozdemir H, et al. evaluated the effect of ozone therapy on autogenous bone graft in calvarial defects [39]. They concluded that

ozone therapy provided to new bone formation with an autogenous bone graft in the rat calvarial defect model. Another study also described that ozone therapy was effective on bone formation in calvarial defects of rats [40].

Although ozone therapy is very effective and safe for treatment, there is one problem that a half-life time of ozonated water is about only 30 min. On the other hand, nanobubbles are maintained for more than 6 months in electrolytic solution [28]. The high stability of ONBW allows for bottling and use as a disinfectant solution at both clinical room and patient's home easily. Future studies should compare the irrigation of ozone-inactivated ONBW or other disinfectants and investigate the effects of ONBW to peri-implantitis related to the other kind of implants such as titanium or zirconium implant. In this report, topical application of ONBW for decontamination at peri-implantitis lesion has been proved to be an effective treatment option when coupled with mechanical plaque control.

Conclusion

This case report supports that ONBW might be effective and predictable as an adjunctive therapy for the treatment of peri-implantitis. As far as we know, this is the first report to describe the peri-implantitis treatment with ONBW. Future studies should compare the irrigation of ozone-inactivated ONBW or other disinfectant and investigate the effect of ONBW to peri-implantitis related to the other kind of implant such as titanium or zirconium implant.

Conflict of Interest

The authors have no conflicts of interest directly relevant to the content of this article.

References

1. Lindhe J, Meyle J (2008) Peri-implant diseases: consensus report of the sixth European workshop on periodontology. *J Clin Periodontol* 35: 282-285.
2. Zitzmann NU, Berglundh T (2008) Definition and prevalence of peri-implant diseases. *J Clin Periodontol* 35: 286-291.
3. Mir-Mari J, Mir-Orfila P, Figueiredo R, Valmaseda-Castello'n E, Gay-Escoda C (2012) Prevalence of peri-implant diseases. A cross-sectional study based on a private practice environment. *J Clin Periodontol* 39: 490-494.
4. Mombelli A, Lang NP (1998) The diagnosis and treatment of peri-implantitis. *Periodontol* 2000 17: 63-76.
5. Rosenberg ES, Torosian JP, Slots J (1991) Microbial differences in 2 clinically distinct types of failures of osseointegrated implants. *Clin Oral Implants Res* 2: 135-144.
6. Gloria IL, Mari'a AS, Diana MC, Mari'a VR, Luz AG (2017) Microbiome and microbial biofilm profiles of peri-implantitis: A systematic review. *J Periodontol* 88: 1066-1089.
7. Faggion CM Jr, Listl S, Fru'hauf N, Chang HJ, Tu YK (2014) A systematic review and Bayesian network metaanalysis of randomized clinical trials on non-surgical treatments for peri-implantitis. *J Clin Periodontol* 41: 1015-1025.
8. Faggion CM Jr, Chambrone L, Listl S, Tu YK (2013) Network meta-analysis for evaluating interventions in implant dentistry: The case of peri-implantitis treatment. *Clin Implant Dent Relat Res* 15: 576-588.
9. Chan HL, Lin GH, Suarez F, MacEachern M, Wang HL (2014) Surgical management of peri-implantitis: A systematic review and meta-analysis of treatment outcomes. *J Periodontol* 85: 1027-1041.
10. Jepsen S, Berglundh T, Genco R (2015) Primary prevention of peri-implantitis: Managing peri-implant mucositis. *J Clin Periodontol* 42: S152-S157.
11. Tonetti MS, Chapple IL, Jepsen S, Sanz M (2015) Primary and secondary prevention of periodontal and peri-implant diseases introduction to, and objectives of the consensus from the 11 European Workshop on Periodontology. *J Clin Periodontol* 42: S1-S4.
12. Muthukuru M, Zainvi A, Esplugues EO, Flemmig TF (2012) Non-surgical therapy for the management of peri-implantitis: A systematic review. *Clin Oral Implants Res* 23: 77-83.
13. Lang NP, Berglundh T, Heitz-Mayfield LJ, Pjetursson BE, Salvi GE, et al. (2014) Consensus statements and recommended clinical procedures regarding implant survival and complications. *Int J Oral Maxillofac Implants* 19: 150-154.
14. Bocci VA (2006) Scientific and medical aspects of ozone therapy. *State of the art. Archives of Medical Research* 37: 425-435.
15. Ripamonti CI, Cislighi E, Mariani L, Maniezzo M (2011) Efficacy and safety of medical ozone (O(3)) delivered in oil suspension applications for the treatment of osteonecrosis of the jaw in patients with bonemetastases treated with bisphosphonates: preliminary results of a phase I-II study. *Oral Oncology* 47: 185-190.
16. Bocci V (2004) Ozone as Janus: this controversial gas can be either toxic or medically useful. *Mediators of Inflamm* 13: 3-11.
17. Grigor'ian A, Grigor'iants L, Guchetl M (2007) Experimentalmorphological study of the anti-inflammatory action of ozone-perfluorane complex application. *Stomatologiia (Mosk)* 87: 4-9.
18. Seidler V, Linetskiy I, Hubálková H, Stankova H, Smucler R, et al. (2008) Ozone and its usage in general medicine and dentistry. A review article. *Prague Medical Report* 109: 5-13.
19. Monte AD, Zee HVD, Bocci V (2005) Major ozonated autohemotherapy in chronic limb ischemia with ulcerations. *J Altern Complemen Med* 11: 363-367.
20. Baysan A, Lynch E (2004) Antimicrobial effects of ozone on caries. In: Lynch E, editor. *Ozone: the revolution in dentistry*. Quintessence Publishing Co: London, UK, pp: 165-172.
21. Baysan A, Lynch E (2004) Effect of ozone on the oral microbiota and clinical severity of primary root caries. *Am J Dent* 17: 56-60.
22. Nagayoshi M, Kitamura C, Fukuizumi T, Nishihara T, Terashita M (2004) Antimicrobial effect of ozonated water on bacteria invading dentinal tubules. *J Endod* 30: 778-781.
23. Huth KC, Paschos E, Brand K, Hickel R (2005) Effect of ozone on non-cavitated fissure carious lesions in permanent molars - a controlled prospective clinical study. *Am J Dent* 18: 229-232.
24. Huth KC, Jakob FM, Saugel B, Cappello C, Paschos E (2005) Effect of ozone on oral cells compared with established antimicrobials. *Eur J Oral Sci* 114: 435-440.
25. Ebensberger U, Pohl Y, Filippi A (2002) PCNA-expression of cementoblasts and fibroblasts on the root surface after extraoral rinsing for decontamination. *Dent. Traumatol* 18: 262-266.
26. Nagayoshi M, Fukuizumi T, Kitamura C, Yano J, Terashita M, et al. (2004) Efficacy of ozone on survival and permeability of oral microorganisms. *Oral Microbiol. Immunol* 19: 240-246.
27. Chiba K, Takahashi M (2008) Nano-bubble Production Method. *Japan Patent P4144669*.
28. Wang S, Liu M, Dong Y (2013) Understanding the stability of surface nanobubbles. *J Phys Condens Matter*. 8: 184007.
29. Hayakumo S, Arakawa S, Takahashi M, Kondo K, Mano Y, et al. (2014) Effects of ozone nano-bubble water on periodontopathic bacteria and oral cells - in vitro studies. *Sci Technol Adv Mater* 8: 1-7.
30. Hayakumo S, Arakawa S, Mano Y, Izumi Y (2013) Clinical and microbiological effects of ozone nano-bubble water irrigation as an adjunct to mechanical subgingival debridement in periodontitis patients in a randomized controlled trial. *Clin Oral Investig* 17: 379-388.

31. Bocci V, Borrelli E, Travagli V, Zanardi I (2009) The ozone paradox: ozone is a strong oxidant as well as a medical drug. *Med Res Rev* 29: 646-682.
32. Daniluk M, Fryczkowski M, Wielicki Z (2000) Application of ozone therapy in chronic inflammation of the urinary bladder. *Ortop Traumatol Rehabil* 2: 61-63.
33. Bocci V, Zanardi I, Borrelli E, Travagli V (2012) Reliable and effective oxygen-ozone therapy at a crossroads with ozonated saline infusion and ozone rectal insufflation. *J Pharm Pharmacol* 64: 482-489.
34. Filippi A (1997) Ozone in oral surgery-current status and prospects. *Ozone Sci Eng* 19: 387-393.
35. Nogales CG, Ferrari PH, Kantorovich EO, Lage-Marques J (2008) Ozone therapy in medicine and dentistry. *J Contemp Dental Pract* 9: 75-84.
36. Azarpazhooh A, Limeback H (2008) The application of ozone in dentistry: a systematic review of literature. *J Dentist* 36: 104-116.
37. Zimmermann D, Waltimo T, Filippi A (2012) Ozonized water in dental traumatology-a preliminary study on the treatment of avulsed teeth, in vitro. *Ozone Sci Eng* 34: 484-488.
38. Erdemci E, Gunaydin Y, Sencimen M, Bassorgun I, Ozler M (2014) Histomorphometric evaluation of the effect of systemic and topical ozone on alveolar bone healing following tooth extraction in rats. *Int J Oral Maxillofac Surg* 43: 777-783.
39. Ozdemir H, Toker H, Balci H, Ozer H (2013) Effect of ozone therapy on autogenous bone graft healing in calvarial defects: a histologic and histometric study in rats. *J Periodont Res* 48: 722-726.
40. Kazancioglu HO, Ezirganli S, Aydin MS (2013) Effects of laser and ozone therapies on bone healing in the calvarial defects. *J Craniofac Surg* 24: 2141-2146.